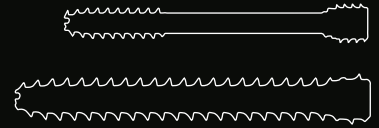


# CASE STUDY



## Metacarpal Fracture treated with Medartis CCS 3.0, 4.0

### The Surgeon

#### Dr. David V. Tuckman

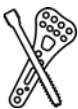Dr. Tuckman is a board-certified orthopaedic surgeon specializing in surgery of the hand and upper extremity in Great Neck, NY. He is also an Assistant Professor of Orthopaedic Surgery at Zucker School of Medicine at Hofstra/Northwell.

### The Case



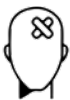#### Indication

Percutaneous fixation of metacarpal fractures is an evolving technique in hand surgery. Transverse fractures can be treated very effectively with a standard compression screw. Oblique or spiral fractures are better treated with a fully threaded non-compression screw to prevent shortening and displacement of the fracture.



#### Product Used

Medartis CCS 3.0 partially threaded and CCS 4.0 fully threaded, headless cannulated screw.



#### Patient History

Patient is a 55-year-old woman who suffered a hand injury after a fall. On examination there was a rotational deformity of the ring finger. The X-rays showed a fracture of the 4<sup>th</sup> and 5<sup>th</sup> metacarpals.



### Pre-Operative Plan

Our options for treatment included formal ORIF with plate and screws, pinning and percutaneous screw fixation. Percutaneous fixation has many advantages including less soft tissue dissection, no pin irritation, no need for a cast and a faster recovery.

The fourth metacarpal fracture has a narrow canal and can typically only accommodate a 3.0mm screw. The 2<sup>nd</sup>, 3<sup>rd</sup> and 5<sup>th</sup> metacarpals generally have a wider canal and can usually accommodate a larger 4.0mm screw. Due to the oblique nature of the 5<sup>th</sup> metacarpal fracture in this case, the use of the Medartis CCS 4.0, fully threaded, headless screw was elected. This has the advantage of not overcompressing the fracture which can lead to fracture displacement.

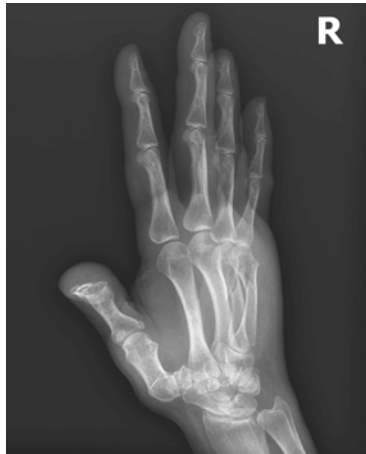

Figure 1

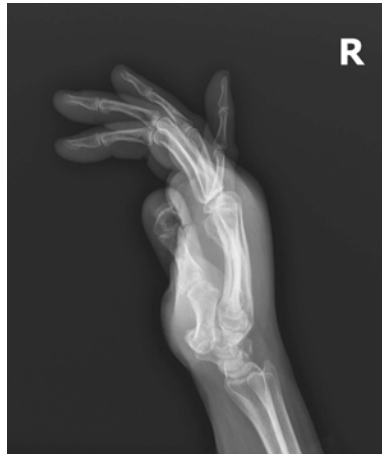

Figure 2

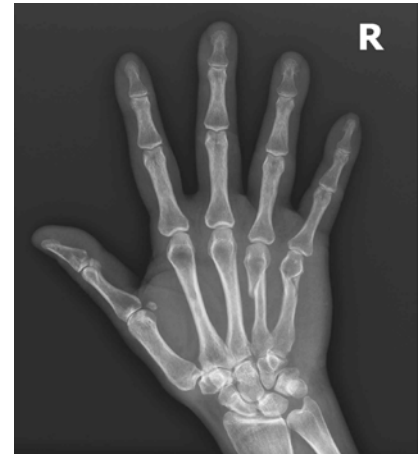

Figure 3



### Treatment

The fourth metacarpal was fixed with a CCS 3.0, partially threaded screw and the fifth metacarpal was treated with a CCS 4.0, fully threaded screw. Patient was placed in a volar splint to the MP joints post-op and at one week post-op was placed in a removal splint which she removed to perform home exercises and to shower.

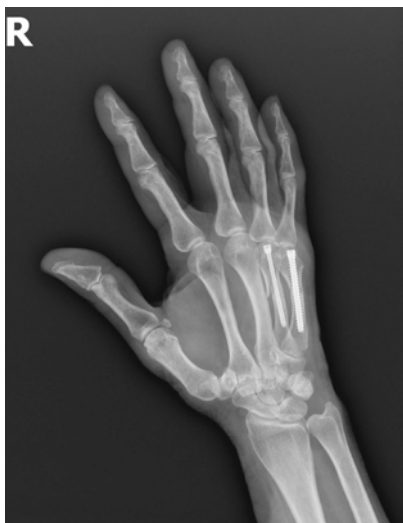

Figure 4

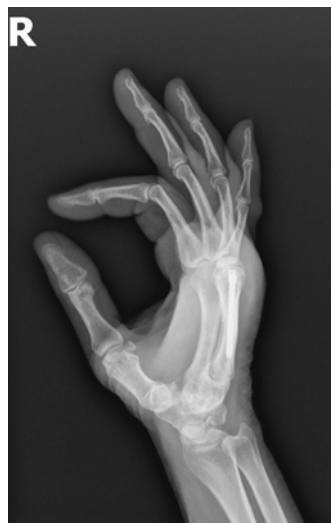

Figure 5

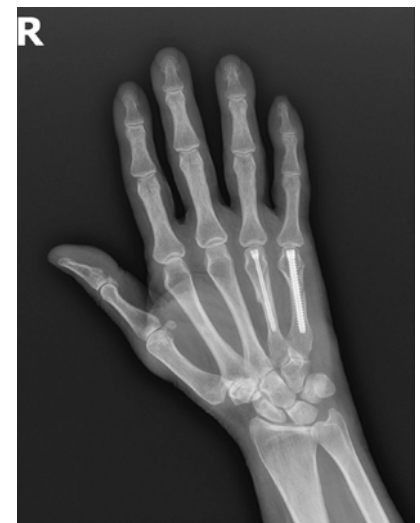

Figure 6

## Follow-Up: Six weeks



### Post-Operative Results

The fracture was healed at six weeks post-op and the patient had regained her full range of motion at that time.

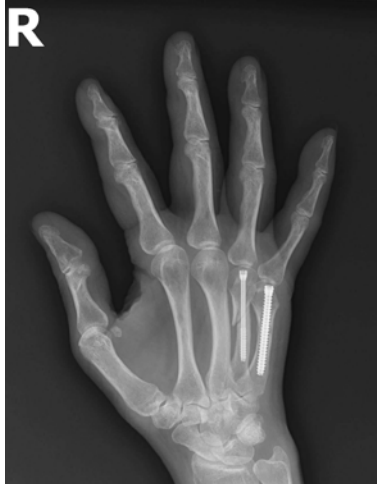

Figure 7

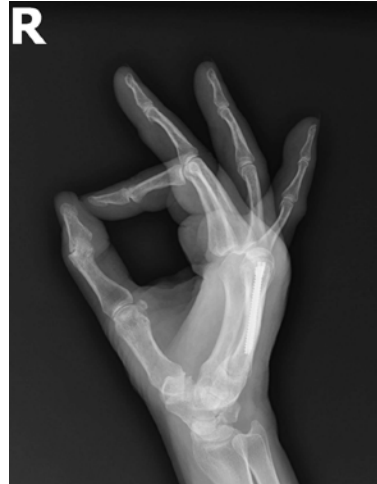

Figure 8

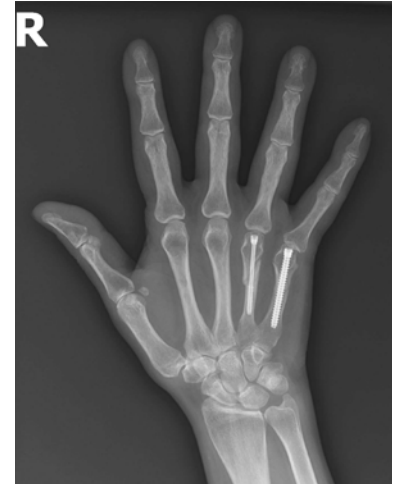

Figure 9



### Conclusion

Metacarpal fractures treated with Medartis cannulated compression screws provide the patient with the latest in metacarpal fracture fixation allowing early return to function.

Disclaimer: This information is intended to demonstrate the Medartis portfolio of medical devices. A surgeon must always rely on her or his own professional clinical judgment when deciding whether to use a particular product when treating a particular patient. Medartis is not giving any medical advice. The devices may not be available in all countries due to registration and / or medical practices. For further questions, please contact your Medartis representative ([www.medartis.com](http://www.medartis.com)). This information contains CE-marked products.  
For US only: Federal law restricts this device to sale by or on the order of a physician.